

Infarcted Wandering Spleen: Case Report from Tirunesh Beijing General Hospital, Addis Ababa, Ethiopia

Mengistu Solomon Sefu^{1,*}, YabsiraMichael Tsegaye¹, Michael Berega Sibhat^{2,*}

¹Department of Surgery, Yekatit 12 Hospital Medical College, Addis Ababa, Ethiopia

²Department of Surgery, Tirunesh Beijing General Hospital, Addis Ababa, Ethiopia

Email address:

Mbsibhat@gmail.com (Michael Berega Sibhat), Mentu2005@gmail.com (Mengistu Solomon Sefu)

*Corresponding author

To cite this article:

Mengistu Solomon Sefu, YabsiraMichael Tsegaye, Michael Berega Sibhat. Infarcted Wandering Spleen: Case Report from Tirunesh Beijing General Hospital, Addis Ababa, Ethiopia. *Reports*. Vol. 3, No. 1, 2023, pp. 7-10. doi: 10.11648/j.reports.20230301.12

Received: February 21, 2023; **Accepted:** April 7, 2023; **Published:** April 15, 2023

Abstract: Wandering spleen or hypermobile spleen results from the elongation or maldevelopment of the spleen's suspensory ligaments. It is rare clinical entity with fewer cases reports worldwide. It is found mostly in children and in adult it is said to be common in females of reproductive age group. Its clinical presentation is different from asymptomatic palpable abdominal mass, intermittent abdominal discomfort due to torsion and spontaneous detorsion to acute abdomen due to torsion with subsequent ischemia and infarction. Because of the rarity of the condition the patient might end with global spleen infarction with splenectomy unless the physician has high index of suspicion. Here we will present a case report of a 19 year old female patient who presented with abdominal pain, vomiting, nausea, anorexia and fever of 3 days duration. Has abdominal tenderness with leukocytosis and abdominal ultrasound finding of anechoic splenic lesions with peritoneal collection. Due to lack of other imaging modalities, exploratory laparotomy was done with an impression of ruptured splenic abscess. The spleen was frankly infarcted with 720 degrees of torsion with no ligaments attachment. Total splenectomy was done and the patient was vaccinated with pentavalent vaccine during her discharge. Even though wandering spleen is rare conditions, one has to consider as differential diagnosis in patient with acute presentation of left upper quadrant abdominal pain with later generalized. And if possible early high index of suspicion might salvage the spleen.

Keywords: Wandering Spleen, Infarcted Spleen, Peritonitis, Exploratory Laparotomy

1. Introduction

The spleen develops from the mesoderm in the dorsal mesogastrium. The spleen is fixed at left hypogastrium with ligaments which are the embryological condensations of the peritoneum. These ligaments include splenorenal, gastrosplenic, splenocolic and splenophrenic. Abnormality or absence of these ligaments can lead the spleen to be abnormally hypermobile. [1, 2].

Due to the laxity of these ligaments the spleen will be hypermobile in individual at risk. The condition can be either congenital or acquired. In the case of congenital the individual will have failed development of the suspensory ligaments of the spleen. Hormonal effect of pregnancy and abdominal wall laxity are proposed as determinant factors for acquired cases. There are about 500 cases reported in the literature all over the world with incidence of less than 0.2%.

This condition can affect all age groups of population. Particularly, it is common in pediatrics and reproductive age of female adults due to the hormonal effect. [3-5].

The clinical manifestations of wandering spleen are varying from asymptomatic to acute abdominal presentation. Those patients with mild pain might have palpable abdominal mass. Those with splenic torsion will have acute severe abdominal pain with diagnosis challenge due to the rarity of the case. There are case reports of wandering spleen with colonic obstruction, and pelvic mass. [4, 6, 7].

Multiple imaging modalities used for the diagnosis of wandering spleen. These include abdominal ultrasound with Doppler to check splenic blood flow. Other modality is spiral CT scan can be used but it is not easily available. The typical findings of CT scan of wandering spleen are: absence of the

spleen in normal location, and lower abdominal or pelvic mass with homogeneous or heterogeneous splenic parenchyma. [8] The options of treatment stated in literatures are operative which includes splenopexy or splenectomy. If patient presented with viable wandering spleen either laparoscopic or open splenopexy can be used as treatment option. Those patients presented with infarcted wandering spleen should be treated with splenectomy. [9, 10].

2. Case Summary

A 19 year old female patient presented with sudden onset dull aching type of left upper quadrant abdominal pain, vomiting, nausea, anorexia, and high grade intermittent fever of 3 days duration. Other than this she has no other complaints or history of known chronic illnesses. For these complaints, she visited private hospital and referred to our hospital with impression of generalized peritonitis secondary to perforated viscus.

During our evaluation, she was tachycardia, tachypnea, and febrile but she was maintaining her blood pressure and oxygen saturation. Has direct and rebound tenderness over the upper abdomen which was more over the left upper quadrant. No other pertinent positive findings on other systems.

On laboratory investigations she was having leukocytosis with left shift and liver and renal functions test was normal. Random blood sugar was normal and she was non-reactive for retroviral serology study.

Abdominal ultrasound showed heterogeneous anechoic lesions over the spleen with moderate free peritoneal collection within the peritoneum.

With impression of peritonitis secondary to ruptured splenic abscess we started her on double antibiotics and resuscitated with crystalloid. We planned for Abdominal CT scan with contrast but it wasn't available in our hospital and the patient couldn't afford outside. For this reason, we decided to explore her after we explained everything to her and informed written consent was taken.

She was explored her through midline vertical abdominal incision. There was about 200cc hemorrhagic fluid in peritoneum and the spleen was frankly infarcted and was twisted 720 degrees counter clockwise over its pedicle and has no ligaments attachment.(See figures 1 and 2) The fluid was sucked out and the infarcted spleen was resected (we haven't untwisted as the whole spleen was frankly gangrenous). After we secured our stump and checked the hemostasis, we lavage the abdomen with warm saline and the abdomen closed in layers after count declared correct. The patient was extubated on table and transferred to recovery room with stable vital signs. Post operatively, she was given double antibiotics and analgesics and her 4th post-operative day she was given pentavalent vaccine and advice on possibility of infection at any time. Currently, she is on follow up at surgical referral clinic and has no complications till this report is written.

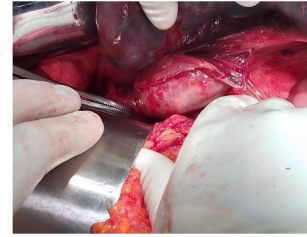


Figure 1. The twisted splenic pedicle (shown by sponge forceps).

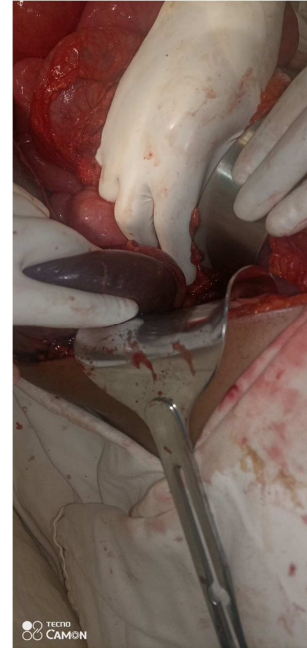


Figure 2. Infarcted Spleen (Held between gloved fingers).

3. Discussion

Wandering spleen is a rare clinical condition characterized by absence or laxity of the spleen leading to different clinical presentation. The patient might be asymptomatic with incidental finding of the condition, chronic intermittent abdominal pain, or acute abdomen with splenic torsion with infarction. And it is said to be more common in reproductive age of female patient.[11] Our patient is female in reproductive age with acute presentations of abdominal pain of 3 days duration which is consistence with possibility of infarction as stated in other case reports.

The main complication of wandering spleen is acute torsion due to torsion of the splenic pedicle leading to vascular compromise. This vascular compromization will lead splenic ischemia with infarction. Those patients having infarction will be more septic with abdominal pain, tachycardia, fever, leukocytosis and other signs and symptoms. Due to the rare clinical entity of the case misdiagnosis is high and most patients will end with splenectomy. [12, 13].

Our patient was having tachycardia, leukocytosis and upper abdomen tenderness which were diagnosed preoperatively as case of ruptured splenic rupture. But, the intra operative findings were huge spleen with absent

suspensory ligaments and infarcted spleen with 720 degree twisted splenic pedicle. The findings are consistence with reports in other cases. [13-15].

Imaging modalities can help in the diagnosis of wandering spleen especially if torsion is suspected. Ultrasound is widely available but it is operator dependent. CT scan with contrast has high diagnostic accuracy as it can detect the arterial and venous status of the spleen. The drawback of CT is not widely available. [16] Splenic salvage is the treatment of choice in non-infracted patient, especially in younger. But if the patient underwent splenectomy post op follow up and vaccination is a must. Anti-Pneumococcal, Hemophilus influenza, and meningococcal vaccines are indicated before elective splenectomy and shortly after non-elective splenectomy [1, 13, 17].

4. Conclusion

Wandering spleen should be suspected in patient with abdominal pain with palpable mass as the condition is rare and the salvage of the spleen depends on the time of diagnosis. Abdominal ultrasound and CT scan are highly supportive in the diagnosis. Once the diagnosis is suspected or confirmed the patient should undergo either laparoscopic or open surgery and the options of treatment will depend on the intra operative findings whether the spleen is infarcted or not. Splenopexy and splenectomy are options of treatment and splenectomy must be the last option of treatment. After splenectomy the patient must be vaccinated with anti-pneumococcal, hemophilus influenza and meningococcal vaccines.

Authors' Contributions

Mengistu involved in pre-operative preparation, operation and wrote this article. Michael was supervising the surgery and Yabsira assisted intraoperative and post-operative patient follow up.

Consent

A verbal informed consent was obtained for the patient for publication of this case report and image taken during intraoperative time.

Competing Interest

We, the authors, declare there is no competing interest.

Abbreviations

CT: Computed Tomography.

Acknowledgements

The authors would like to thank everyone who took part in the management of the patient. Our gratitude also goes to the Tirunesh Beijing General Hospital administration for their

permission to use the patient medical records.

References

- [1] Solomon Bekele Abebe, Yonas Ademe Teferi, Henok T / Silassie Zeleke. Wandering spleen with torsion presenting as a rare case of acute abdomen. Clin Surg Res Commun 2021.
- [2] LorenzoCrepaz, Alberto Di Leo, Giuseppe Borzellino, Paola Pomini and Michele Genn. The wandering spleen: case report of laparoscopic splenectomy in a pregnant woman. Bulletin of the National Research Centre (2022) 46: 273.
- [3] Jawad M, Yusuf M H, Al Doaibel K A, et al. Wandering Spleen: A Rare Case From the Emergency Department. Cureus 15 (1): 2023.
- [4] Sergi W, D'Ugo S, Marchese TRL, Garritano S, Perrone F, Manoochehri F, Spampinato M. Colonic obstruction caused by wandering spleen: Case report and literature review. Int J Case Rep Images 2021; 12: 101203Z01WS2021.
- [5] MS Ismail. Wandering spleen with splenic vein thrombosis: A Case Report. East Cent. Afr. J. surg. 2016.
- [6] Kariya CM., Fowler DH., Stratton P. Wandering spleen caused by subcapsularhaemorrhage. BMJ Case Rep Published Online: 2018.
- [7] S. Zarrintanet. Al. A wandering spleen presenting as a pelvic mass: case report and review of the literature. VIA MEDICA: 2007.
- [8] Mohammad ShazibFaridi, Ashish Kumar, Lubnainam, Razi Shahid. Wandering Spleen - A diagnostic Challenge: Case Report and Review of Literature. Malays J Med Sci: 2014.
- [9] Soo-Hong Kim, Yong-Hoon Cho, Hae-Young Kim. Two cases of splenic infarction due to torsion of wandering spleen requiring laparoscopic splenectomy in adolescent girls. Pediatr Emerg Med J, 2020.
- [10] Raid Alghamdi, AmerAlzahrnai, AbdulazizAlosaimi, and Ibrahim Albabtain. Infarcted wandering spleen: A case report from Saudi Arabia. Journal of Surgical Case Reports, 2021.
- [11] RaghebAssaf, BaraaShebli, AyhamAlzahrnan, Ahmad Rami Rahmeh, Ali Mansour, Rama Hamza, EhabAlaasyAlkushti, and KusayAyoub. Acute abdomen due to an infarction of wandering spleen: case report. Journal of Surgical Case Reports, 2020.
- [12] Rey Valle's YS, Fonseca Sosa FK, Valle's Gamboa M, Quesada Marti'nez E. Torsio'n de bazoecto'pico. Cir Esp. 2020; 98: 418–419.
- [13] AmanSharma andGisella Salerno. A torted wandering spleen: a case report. Journal of Medical Case Reports 2014.
- [14] Evangelos Koliakos, Xenofon Papazarkadas, Marwan-Julien Sleiman, Ioannis Rotas, and Michel Christodoulou. Wandering Spleen Volvulus: A Case Report and Literature Review of This Diagnostic Challenge. Am J Case Rep, 2020.
- [15] Noemi Cantone, Caterina Gulia, Vittorio Miele, Margherita Trinci, and Vito Briganti. Wandering Spleen and Organoaxial Gastric Volvulus after Morgagni Hernia Repair: A Case Report and Review of the Literature. Hindawi Publishing Corporation Case Reports in Surgery, 2016.

- [16] Ömer Özçağlayan, Tuğba İlker Özçağlayan, and Bozkurt Gülek. Contrast-Enhanced Computed Tomographic Findings of the Wandering Spleen: A Case Report. *Med Bull Sisli Etfal Hosp* 2019; 53 (1): 76–79.
- [17] Leci-Tahiri, L., Tahiri, A., Bajrami, R., &Maxhuni, M. (2013). Acute abdomen due to torsion of the wandering spleen in a patient with Marfan Syndrome. *World Journal of Emergency Surgery*, 8 (1), 30.